

The frequency of different morphological variants of lichen planus in HCV seropositive patients

Rabia Javaid, Saelah Batool, Ashba Cheema, Ayesha Anwar, Anila Asghar, Aisha Ghias, Muhammad Azam Bokhari, Shahbaz Aman

Department of Dermatology, Services Institute of Medical Sciences/ Services Hospital Lahore.

Abstract

Background Pakistan has a high prevalence of hepatitis C virus (HCV) infection. There is a well known association between HCV infection and lichen planus (LP), which is an immune mediated mucocutaneous disorder.

Objective To determine the frequency of different morphological variants of lichen planus in HCV seropositive patients in a tertiary care hospital.

Materials and Methods In this cross-sectional study, a total of 200 patients of LP who were seropositive for HCV infection (detected by third generation ELISA) were enrolled after written informed consent. Cutaneous examination was done in all the patients and the morphological types of LP were ascertained.

Results Out of 200 patients in the study, 101 (50.5%) were males and 99 (49.5%) were females. The mean age of the patients was 38.5 ± 13.7 years. Isolated variants were found in 89% (n=178) while mixed lesions (combination of 2 or more clinical types) were found in 11% (n=22) of patients. Among isolated variants, hypertrophic LP was the predominant clinical type (25%, n=50) followed by classic (21%, n=42), oral (17.5%, n=35), pigmented (11%, n=22), annular (5.5%, n=11), follicular (4.5%, n=9), atrophic (4%, n=8) and plaque-like (0.5%, n=1). Oral involvement was most common in hypertrophic LP and was absent in pigmented, annular, follicular, atrophic and plaque-like LP. Among the mixed variants, hypertrophic and classic was the most frequent combination (3.5%, n=7), followed by hypertrophic and pigmented (3%, n=6), classic and pigmented (1.5%, n=3), atrophic and follicular (1%, n=2), annular and follicular (0.5%, n=1), annular and atrophic (0.5%, n=1), annular and hypertrophic (0.5%, n=1) and classic and plaque-like (0.5%, n=1)..

Conclusion There are various morphological types of lichen planus in association with HCV infection in our patients. Recognition of these types of LP should raise the vigilance for HCV workup. This would lead to early diagnosis of this miserable chronic infection and prevent its complications.

Key words

Lichen planus; morphological types; hepatitis C virus infection.

Introduction

Lichen planus (LP) is immune mediated

Address for correspondence

Dr. Saelah Batool, Assistant Professor,
Department of Dermatology,
Services Hospital, Lahore.
Ph: 03014699614
Email: saelahbatool@rocketmail.com

inflammatory dermatosis characterized by polygonal, flat-topped, shiny, pruritic, violaceous papules that may coalesce to form plaques. It involves the skin, and mucous membranes.^{1,2} Scalp, hair and nails can also be affected. The global prevalence of lichen planus is about 1-2%.³ There is a slightly greater predilection for females as compared to males

(3:2).⁴

The clinical presentation of LP is variable.^{5,6} The classic cutaneous lesions are pruritic, flat topped, violaceous papules and plaques traversed by white streaks called Wickham's striae. Other clinical types are hypertrophic, atrophic, follicular, linear, actinic, pigmented, annular, actinic, guttate, erosive/ulcerative, bullous, linear, segmental, LP of palms and soles. In the mucosa, oral LP (OLP) presents as reticular, erosive, atrophic and plaque-like forms. Mixed lesions are commonly encountered.⁷

It is an autoimmune disease, although genetic, viral, iatrogenic (dental amalgam and radiotherapy) and psychological factors have also been implicated.⁸ There is a possible role of hepatitis C virus (HCV) in the etiology of lichen planus.⁹ The association between LP and HCV was first described by Mokni *et al.* in 1991.¹⁰ Though studies done later have shown conflicting results^{11,12} most have favoured this association. Lodi's meta-analysis reveals that LP leads to an increased risk of being HCV seropositive and HCV seropositive patients are at increased risk of developing LP.¹³ In the most recent studies, the seroprevalence of HCV infection in LP patients was found to be 3.1% in Iraq¹⁴, 21.4% in Nigeria¹⁵ and 100% in Egypt.¹⁶ In Pakistan, this figure is reported to be 6.3%.¹⁷

International literature on different morphological variants of LP encountered in hepatitis C infected patients is variable. Ukono's study in Nigeria documents hypertrophic LP as the commonest type (28.6%), followed by mixed hypertrophic and annular (4.8%), and ulcerative (2.4%) type.¹⁵ In a Moroccan study, no patient had hypertrophic LP. This study particularly emphasized the association of oral LP with HCV where reticular (51%) and erosive (34%) variants of oral LP were most commonly

observed, while plaque-like (23%), atrophic (20%), classic (6%) and pigmented (6%) variants of cutaneous LP were observed to a lesser extent.¹⁸ A recent Indian study has also reported this association.¹⁹ In Pakistan, however, very few studies have been done in this regard. In Akhter's observational study on 41 HCV positive LP patients, mixed (32%) and hypertrophic (31%) LP were the most frequent clinical variants, followed by erosive (20%), atrophic (12%) and follicular (12%) variants.²⁰

The present study was designed to document the morphological types of LP in HCV seropositive patients in our community and to compare it with previous studies which show variable results. Also, local literature is scarce and covers only a small sample size while in our study a larger sample size was used. Considering the high prevalence of hepatitis C in Pakistan, and the fact that the infection is often associated with LP and may be asymptomatic, future LP patients presenting with these most common morphological variants would not be missed for HCV screening. In this way occult HCV infection would be discovered and patients would be managed earlier.

Patients and Methods

This cross-sectional study was conducted at the department of Dermatology, Services Hospital Lahore over one year from March 2013 to 2014. A total of 200 patients with clinical diagnosis of LP and who were found to be anti-HCV positive (detected by third generation ELISA) were enrolled in the study after written informed consent. All ages and both genders were included. Histological confirmation of LP was done in doubtful cases.

Patients with lichenoid drug eruptions, or those on systemic drugs causing lichenoid eruptions such as heavy metals, antimalarials, NSAIDs,

pencillamine, diuretics, beta blockers, nifedipine, ACE inhibitors, phenothiazines, dapsone, chemotherapeutic agents (5 fluorouracil, hydroxyurea), allopurinol and iodides were excluded from the study. Those with concomitant systemic illnesses like diabetes mellitus, ulcerative colitis, SLE and myasthenia gravis were also excluded.

Patients' biodata were recorded, cutaneous examination was done in all the patients and the morphological variants of LP were noted.

The data collected was analyzed using SPSS software version 17. Mean and standard deviation was calculated for quantitative variables like age. Qualitative variables like sex of patients, morphological types of lichen planus were presented as frequency and percentages.

Results

A total of 200 patients of LP who were seropositive for HCV were included in this study. The age range in this study was 17-85 years. The mean age of the patients was 38.49 ± 13.66 years. Majority of the patients (57.5%) were 21-40 years old (**Table 1**).

Out of 200 patients in the study, 101 (50.5%) were males and 99 (49.5%) were females. The female to male ratio was 1:1.04 (**Figure 1**).

Table 1 Distribution of patients by age

Age (Years)	n=200 (%)
1 – 10	0
11 – 20	12 (6%)
21 – 30	56 (28%)
31 – 40	59 (29.5%)
41 – 50	38 (19%)
51 – 60	24 (12%)
61 – 70	5 (2.5%)
71 – 80	5 (2.5%)
>80	1 (0.5%)
Mean±SD	38.49±13.66
Range	17 – 85

Key: SD=Standard deviation

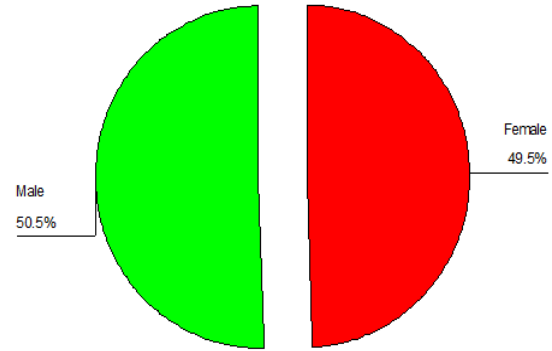


Figure 1 Distribution of patients by Sex (n=200)

Table 2 Frequency of different morphological variants of LP among HCV seropositive patients (n=200)

Morphological variants of LP	N	Percentage (%)
Isolated	178	89%
Mixed	22	11%
Total	200	100%

Table 3 Frequency of isolated variants of LP among HCV seropositive patients (n=178)

Types of Isolated variants	N	Percentage (%)
Hypertrophic	50	25 %
Classic	42	21 %
Oral	35	17.5 %
Pigmented	22	11 %
Annular	11	5.5 %
Follicular	9	4.5 %
Atrophic	8	4 %
Plaque-like	1	0.5 %
Total	178	89%

Isolated variants of LP were found in 178 patients (89%) while mixed variants (combination of 2 or more clinical types) were found in 22 patients (11%) (**Table 2**). Among isolated variants, hypertrophic LP was the predominant clinical type (n=50, 25%) followed by classic (n=42, 21%), oral (n=35, 17.5%), pigmented (n=22, 11%), annular (n=11, 5.5%), follicular (n=9, 4.5%), atrophic (n=8, 4%) and plaque-like (n=1, 0.5%) (**Table 3**).

Involvement of the oral cavity was seen mostly in hypertrophic LP, where 19 out of 50 patients

Table 4 Frequency of mixed variants of LP among HCV seropositive patients (n=22)

Types of mixed variants	N	Percentage (%)
Hypertrophic and classic	7	3.5 %
Hypertrophic and pigmented	6	3 %
Classic and pigmented	3	1.5 %
Atrophic and follicular	2	1 %
Annular and follicular	1	0.5 %
Annular and atrophic	1	0.5 %
Annular and hypertrophic	1	0.5 %
Classic and plaque-like	1	0.5 %
Total	22	11%

(38%) had oral lesions. They were seen to a lesser extent in classic LP where 10 out of 42 patients (23.8%) had oral lesions. Oral lesions were absent in pigmented, annular, follicular, atrophic and plaque-like LP. Among the 22 patients with mixed variants, hypertrophic and classic was the most frequent combination (3.5%, n=7), followed by hypertrophic and pigmented (3%, n=6), classic and pigmented (1.5%, n=3), atrophic and follicular (1%, n=2), annular and follicular (0.5%, n=1), annular and atrophic (0.5%, n=1), annular and hypertrophic (0.5%, n=1) and classic and plaque-like (0.5%, n=1) (Table 4).

Discussion

This prospective case series was carried out in 200 patients with diagnosis of cutaneous lichen planus in patients with hepatitis C virus infection to find out the frequency of various morphological variants of LP.

The results of this study showed that most of the patients had isolated lesions of LP (89%). Among the isolated type of lesions, hypertrophic LP was the most common (25%) followed by classic LP (21%), and then oral LP (17.5%).

In literature, there are several studies which have described the frequency and morphological patterns of lichen planus among patients with

HCV infection. The results of these studies are different from one another.

In our study, the most common variant of LP in HCV positive patients were isolated type (89%). The hypertrophic LP was found to be the most frequently occurring isolated variant (25%). In a study by Ukono *et al.*,¹⁵ hypertrophic type of lesions were the most frequent (28.6% patients). Akhtar and colleagues²⁰ also found hypertrophic LP to be the most frequent variant (31%). The second most common variant of LP in our study was classic LP (21%). This observation was quite different from a study by Hakkou F *et al.*²¹ who described classic lesions in 6% patients. Erosive LP(oral) was observed in 17.5% patients in our study. Hakkou *et al.*²¹ described erosive lesions in 28% of patients in their study. While in a local study by Akhtar *et al.*²⁰ the erosive lesions were present in 20% patients.

In our study, pigmented lesions were present in 11% patients. However, in the study by Hakkou *et al.*²¹ pigmented lesions were seen in 6% patients. Annular lesions were present in 5.5% patients in our study. Ukono's study¹⁵ showed that annular lesions were present in 4.8% patients. Lesions of follicular LP were encountered in 4.5% patients in our study. Hakkou *et al.*²¹ encountered follicular LP in 4.8% patients, while Akhtar *et al.*²⁰ described follicular LP in 5% patients in their study. Atrophic lesions were present in 4% patients in our study. Hakkou *et al.*²¹ described atrophic lesions in 20% patients, while Ukono *et al.*¹⁵ described them in 2.4% patients. However, Akhtar *et al.* described atrophic lesions in 12% patients of their study population.²⁰ Plaque-like lesions were present in only 0.5% patients in our study. On the contrary, Hakkou *et al.*²¹ reported the presence of plaque-like lesions in 23% patients.

In our study, mixed type of lesions (combination

of two morphological types) were present in 11% patients. In a previous study by Akhtar *et al.*, mixed lesions were described in 32% patients.²⁰ However, the results of our study are important as we have described in detail the combination of different types of mixed lesions. We observed that hypertrophic and classic types were the most common combination of mixed LP (3.5%), followed by hypertrophic and pigmented LP (3%).

In the work done by Ukono *et al.*¹⁵ the most common combination of mixed lesions was that of annular and follicular LP (9.5% patients), followed by hypertrophic and annular LP (4.8% patients) and then hypertrophic and follicular (2.4% patients). When compared with our results, annular and follicular were present in only 1.8% patients, hypertrophic and annular in 1.8% patients, and none of the patients in our study had hypertrophic and follicular pattern.

The mean age of the patients in our study was 37.63±5.42 years with the majority of patients included in the age range of 21–50 years i.e. 76.5%. Some authors have reported that LP usually appears in the middle age group.¹³ Involvement at a relatively younger age is found in this series; i.e. majority of patients (75.5%) fall in the age group of 21-50 years. This observation is not similar to the observations of Persić *et al.*²² and Omal *et al.*²³ who showed an increased prevalence of lichen planus in middle-aged patients (40-60 years).

In our study, we did not find any predisposition to the gender as the female to male ratio was almost similar (1:1.04). Gonzaga *et al.* found in their study that men (62.2%) dominated over women (37.8%).²⁴ The results obtained by Persić *et al.* indicated a significant female predominance (67.5% versus 32.5%).²² Bajaj *et al.* also showed a female predominance. Of the 95 patients seen, 57.9% were female and 42.1%

male (1:1.38).²⁵

The significance of our study is that we have not only described the different clinical variants of LP in HCV positive population presenting to us, but have also reported the various combinations in which they may occur in such patients. It can be considered from our study that the presence of two or more different clinical variants of LP in a single patient should raise the vigilance for HCV workup, particularly in our part of the world where its prevalence is high. Those with isolated classic or hypertrophic LP should also be evaluated. This would provide early detection of occult HCV infection, timely management and possibly a better outcome.

Conclusion

Lichen Planus in association with HCV infection, has diverse morphological variants, which may present either in isolation or in combination of more than one different clinical types. Majority of the patients with HCV infection in our study had hypertrophic LP. Involvement of the oral cavity was most commonly seen in this variant. Recognition of these types of LP should raise the vigilance for HCV screening so that occult infection can be diagnosed and treated early and complications can be prevented. We still need large multicentre trials to document the exact frequency of the different clinical types of LP in HCV positive patients in our community.

References

1. Aly DG, Shahin RS. Oxidative stress in lichen planus. *Acta Dermatovenereol Alp Panonica Adriat* 2010; **19(1)**: 3-11.
2. Pittelkow MR, Daoud MS. Lichen planus. In: Wolff GK, Goldsmith L, Katz S, Gilchrest B, Paller A, eds. *Dermatology in general medicine*. 7th ed. New York: McGraw-Hill 2008; 244-55.

3. Eisen D. The evaluation of cutaneous, genital, scalp, nail, esophageal, and ocular involvement in patients with oral lichen planus. *Oral Surg Oral Med Oral Pathol Oral Radiol Endod* 1999; **88(4)**: 431-6.
4. Roopashree MR, Gondhalekar RV, Shashikanth MC, George J, Thippeswamy SH, Shukla A. Pathogenesis of oral LP - A review. *J Oral Pathol Med* 2010; **39(10)**: 729-34.
5. Bermejo-Fenoll A, Sánchez-Siles M, López-Jornet P, Camacho-Alonso F, Salazar-Sánchez N. A retrospective clinicopathological study of 550 patients with oral lichen planus in south-eastern Spain. *J Oral Pathol Med* 2010; **39(6)**: 491-6.
6. Irvine C, Irvine F, Champion RH. Long-term follow-up of lichen planus. *Acta Derm Venereol* 1991; **71**: 242-4.
7. Parashar P. Oral lichen planus. *Otolaryngol Clin North Am* 2011; **44(1)**: 89-107.
8. Waheed Y, Shafi T, Safi SZ, Qadri I. Hepatitis C virus in Pakistan: A systematic review of prevalence, genotypes and risk factors. *World J Gastroenterol* 2009; **15(45)**: 5647-53.
9. Azfar NA, Zaman T, Rashid T, Jahangir M. Cutaneous manifestations in patients of hepatitis C. *J Pak Assoc Dermatol* 2008; **18**: 138-43.
10. Mokni M, Rybojad M, Puppini D Jr, Catala S, Venezia F, Djian R, Morel P. Lichen planus and hepatitis C virus. *J Am Acad Dermatol*. 1991; **24**:792.
11. Das A, Das J, Majumdar G, Bhattacharya N, Neogi DK, Saha B. No association between seropositivity for Hepatitis C virus and Lichen Planus: A case control study. *Indian J Dermatol Venereol Leprol* 2006; **72**:198-200
12. Ansari A, Zamanian A, Farschian M, Borouri R, Mobaien AR. Comparison of seropositivity of HCV between oral lichen planus and healthy control group in Hamedan province. *Our Dermatol Online* 2011; **2(4)**: 181-4
13. Lodi G, Pellicano R, Carrozzo M. Hepatitis C virus infection and lichen planus: A systematic review with meta-analysis. *Oral Dis*. 2010; **16(7)**: 601-12.
14. Strak SK, Al-Hamdi KI, Alabdood MH. A study of lichen planus and its association with Hepatitis C infection. *J Taibah Univ Med Sciences*. 2015; **10(2)**: 222-6.
15. Ukono AB, Uzunmwangho A. Prevalence of hepatitis C virus among lichen planus patients and its clinical patterns at the University of Abuja Teaching Hospital (U.A.T.H), Jwagwalada, Abuja, Nigeria. *Global J Health Sci* 2012; **4(5)**: 113-9.
16. Amer MA, El-Harras M, Attwa E, Raslan S. Lichen planus and Hepatitis virus infection prevalence and clinical presentations in Egypt. *J Eur Acad Dermatol Venereol*. 2007; **21(9)**: 1259-60.
17. Nasreen S, Ahmed Ijaz, Wahid Z. Association of lichen planus: A study of 63 cases. *J Pak Assoc Dermatol* 2007; **17(1)**: 17-20.
18. Konidena A, Pavani BV. Hepatitis C virus infection in patients with oral lichen planus. *Niger J Clin Pract* 2011; **14(2)**: 228-31.
19. Bennion SD. Structure and function of the skin. In: Fitzpatrick JE, Morelli JG, eds. *Dermatology secrets in color*. India: Mosby Elsevier inc 2007:9-16
20. Akhter SJ, Shahid M, Iqbal J, Shakoor A, Raja M. Morphological patterns of lichen planus in patients with anti-hepatitis C antibodies. *J Pak Assoc Dermatol* 2007; **17**: 225-30.
21. Hakkou F, Chbicheb S, Essaid E, El Wady W. Lichen planus and hepatitis C virus infection: An epidemiological study of 149 cases. *Int J Odontostomat* 2012; **6(2)**: 163-8.
22. Persić S, Mihić LL, Budimir J, Situm M, Bulatz V, Krolo I. Oral lesions in patients with lichen planus. *Acta Clin Croat* 2008; **47(2)**: 91-6.
23. Omal P, Jacob V, Prathap A, Thomas NG. Prevalence of oral, skin, and oral and skin lesions of lichen planus in patients visiting a dental school in southern India. *Indian J Dermatol* 2012; **57(2)**: 107-9
24. Gonzaga HF, Gonzaga LH, Buso L, Barbosa CAA, Jorge MA. Prevalence of oral lichen planus in Brazilian patients with cutaneous lichen planus. *Rev. FOB* 1999; **7(3/4)**: 71-5.
25. Bajaj DR, Khoso NA, Devrajani BR, Matlani BL, Lohana P. Oral Lichen Planus: A Clinical Study. *J Coll Physicians Surg Pak* 2010; **20(3)**: 154-7.