

## PhotoDermDiagnosis

# Tense bullae in a young lady

### Section Editor

Amor Khachemoune, MD CSW,

Suny Down State Medical Center, Brooklyn,  
NY, USA

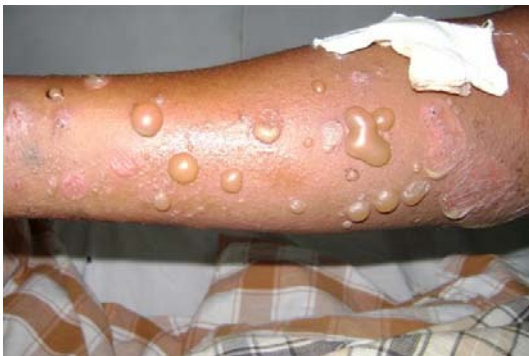Vandana Mehta Rai, Lakshmi Indusri, C.  
Balachandran

Department of Skin & STD, Kasturba Medical College,  
Manipal, India.

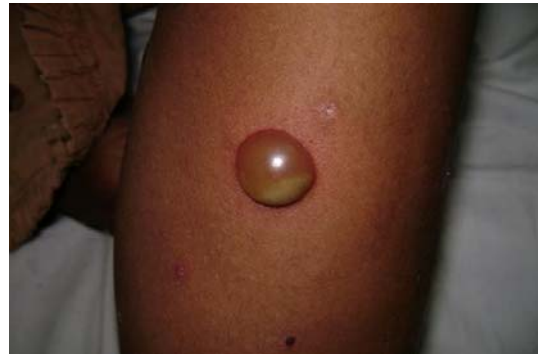A 35-year-old female presented with tense blisters all over body of 2 years duration. Lesions initially started as erythematous papules on an urticated base over chest and subsequently spread to arms, forearms and lower limbs. There was no history of fever, peripheral extension of the lesions, drug intake, family history or systemic complaints.

On clinical examination tense vesicles, pustules and bullae were present in groups on an urticated base along with few erosions over arms, forearms and lower limbs (**Figure 1** and **2**). Few bullae showed half and half sign. Tzanck smear from a fresh vesicle showed mixed infiltrate of eosinophils and neutrophils with absence of acantholytic cells. Biopsy findings are shown in **Figure 3**.

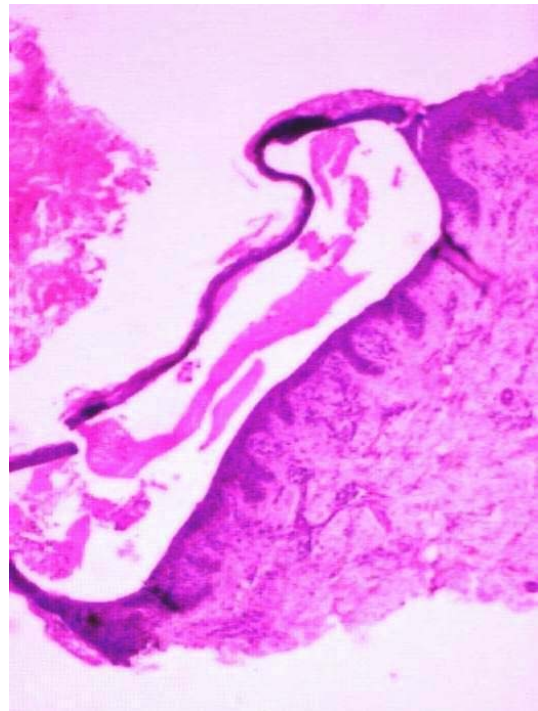
What is your diagnosis?



**Figure 1**



**Figure 2**



**Figure 3**

---

#### Address for correspondence

Dr. Vandana Mehta Rai, Assistant Professor,  
Department of Skin & STD,  
Kasturba Medical College,  
Manipal 576104, Karnataka, India.  
E mail: vandanamht@yahoo.com

## Diagnosis

Pemphigus herpetiformis

## Microscopic findings

Hematoxylin and eosin stained sections showed an intraepidermal blister with mixed infiltrate of eosinophils and neutrophils in the upper dermis. Direct immunofluorescence study showed intraepidermal deposition of IgG and C<sub>3</sub> localized mainly to the upper epidermis.

## Discussion

Pemphigus herpetiformis (PH) is a rare atypical variant of pemphigus which combines clinical features of dermatitis herpetiformis with immunohistological features of pemphigus vulgaris. It is characterized by pruritus, invariable presence of eosinophils, neutrophils in Tzanck smear and tendency to respond to sulphones. Various terms have been used to describe this condition such as “acantholytic herpetiform dermatitis”, “pemphigus controlled by sulphapyridine” and “mixed bullous disease”.<sup>1</sup> Jablonska coined the term ‘pemphigus herpetiformis’ in the year 1975.<sup>2</sup>

Clinically the lesions appear as erythematous urticarial plaques and vesicles in a herpetiform arrangement. Tzanck smear shows eosinophils and neutrophils with no acantholytic cells. Histological findings of PH include eosinophilic spongiosis and subcorneal pustules with no acantholysis and immunofluorescence findings show IgG antibodies against keratinocyte cell surfaces predominantly localized to the upper epidermis.<sup>1,3</sup> Immunoprecipitation, Immunoblotting and ELISA further help in

detecting specific protein component recognized by IgG antibodies.<sup>4</sup>

Desmoglein 1, the target antigen in PH is located in the upper epidermis which explains localization of the immunoreactants in DIF to the upper epidermis.<sup>5</sup> Autoantibodies in classical pemphigus and in PH recognize different epitopes on the same antigen. Autoantibodies in classical pemphigus inhibit adhesive function of desmoglein leading to acantholysis, where as those in PH do not inhibit adhesive function but induce a secondary inflammatory process with the help of complements or other chemotactic factors. PH cases may later evolve into pemphigus vulgaris or foliaceus. PH has a benign clinical course and prognosis is excellent.<sup>6</sup>

Since the clinical presentation of PH is atypical the lesions are initially misdiagnosed as dermatitis herpetiformis, bullous pemphigoid, linear IgA bullous dermatosis, pemphigus foliaceus and IgA pemphigus. Nevertheless severe pruritus seems to be a commonly presenting symptom. Treatment options for PH include dapsone, systemic and topical corticosteroids, sulphapyridine and immunosuppressants.<sup>1</sup>

We here report a case of PH which resembled bullous pemphigoid clinically in a young lady and responded well dapsone and tapering doses of prednisolone.

## References

1. Neha DR, Takashi H, Amagai M. The new pemphigus variants. *J Am Acad Dermatol* 1999; **40**: 649-74.
2. Jablonska S, Chorzelski TP, Beutner EH, Chorzelska J. Herpetiform

- pemphigus, a variable form of pemphigus. *Int J Dermatol* 1975; **14**: 353-59.
3. Kubo A, Amagai M, Hashimoto T *et al*. Herpetiform pemphigus showing reactivity with pemphigus vulgaris antigen. *Br J Dermatol* 1997; **137**: 109-13.
  4. Hashimoto T, Ogawa MM, Konohana A. Detection of pemphigus vulgaris and pemphigus foliaceus antigens by immunoblot analysis using different antigen sources. *J Invest Dermatol* 1990; **94**: 327-31.
  4. Ishii K, Amagai M, Komai A, Ebihara T. Desmoglein 1 and desmoglein 3 are the target auto antigens in herpetiform pemphigus. *Arch Dermatol* 1999; **135**: 943-7.
  5. Amagai M. Pemphigus: autoimmunity to epidermal cell adhesion molecules. *Adv Dermatol* 1996; **11**: 319-52.