

Frequency of mucocutaneous manifestations in HIV positive patients

Sehrish Ashraf, Kehkshan Tahir, Faizan Alam, Ijaz Hussain

Department of Dermatology, Services Institute of Medical Sciences/ Services Hospital, Lahore

Abstract *Objective* To determine the frequency of mucocutaneous manifestations in HIV positive patients.

Methods This descriptive cross-sectional study was conducted at the Outpatient Department of Dermatology and HIV clinic of Services Hospital, Lahore from Jun 10, 2015 to Dec 09, 2015. Total 170 HIV positive patients fulfilling inclusion / exclusion criteria, were assessed on clinical grounds and relevant investigations e.g. KOH preparations, Tzanck smear and histopathology were carried out. These patients were enrolled in the study after taking informed consent. Patient's biodata, CD4 count and mucocutaneous lesions found were recorded on a predesigned proforma.

Results The age ranged between 16 and 60 with a mean of 41.9 ± 8.2 years. There were 113 (66.5%) male patients and 57 (33.5%) female patients. Mucocutaneous manifestations were found in 143 out of 170 (84.1%) patients.

Conclusion A high prevalence of dermatological lesions in HIV infected patients was seen in the present study. Most common mucocutaneous manifestation was viral infections followed by bacterial and fungal infections.

Key words

Mucocutaneous manifestation, HIV, CD4, KOH.

Introduction

Human immunodeficiency virus (HIV) is an RNA virus, which attacks the immune system of the host. This infection is a challenge faced by the entire world. It is a devastating human crisis that has affected many countries. In the year 2009 a total of 33.3 million people was found to be HIV positive all over the world.¹ Sixteen thousand new HIV cases are being reported daily.¹ According to statistics 96,000 people are suffering from HIV/AIDS in Pakistan.²

Skin is the most commonly affected organ in

patients with HIV infection. A wide range of infectious and noninfectious skin lesions develop during the course of the disease and in many, these may be the earliest and the only sign of HIV/AIDS.³ It is almost certain that HIV-infected individuals will develop skin-related disorders some time during the course of HIV disease. The spectrum and frequency of mucocutaneous manifestations may vary in different regions and different populations.^{4,5} These cutaneous disorders are seen in all stages of infection and range from opportunistic infections and inflammatory dermatoses to cutaneous malignancies.⁶ The usual dermatological manifestations seen in HIV patients include pruritus, xerosis, ichthyosis, nodular prurigo, folliculitis, eosinophilic folliculitis, pruritic papular eruption, seborrheic dermatitis, psoriasis, herpes simplex, herpes

Address for correspondence

Dr. Sehrish Ashraf, WMO
Department of Dermatology,
Services Institute of Medical Sciences/
Services Hospital, Lahore
Email: Sehrish.khurram13@gmail.com

zoster, viral warts, mollusca, oral and vaginal candidosis, tinea (including onychomycosis), scabies, basal cell carcinoma, squamous cell carcinoma and Kaposi's sarcoma.⁷ Drug reactions are also common in HIV positive patients.⁸

The frequency of these mucocutaneous manifestations varies between different populations and in different stages of the disease, mainly determined by CD4 count. The normal CD4 cell count in adults ranges from 500-1500 cells per mm³. Alteration in the immune status of the patient along with a low CD4 count has been found to be associated with an increased frequency of cutaneous manifestations but this relation is debatable.^{9,10,11} This study was planned keeping in view that only a few studies on nature and prevalence of HIV associated mucocutaneous manifestations is available in Pakistani population infected with HIV.

Methods

This descriptive cross-sectional study was conducted at the Outpatient Department of Dermatology and HIV clinic of Services Hospital, Lahore over a period of six months from June, 2015 to December, 2015. 170 ELISA-positive HIV patients of either sex, age ranging from 15 to 60 years, having any stage of the disease irrelevant of the CD4 count, were included in the study. HIV positive patients with any duration of disease and treatment, either on HAART or not were also included in the study.

Patients having any other co-morbid condition, e.g. chronic liver disease, chronic renal disease, diabetes mellitus and collagen-vascular disease were excluded from the study.

HIV-positive patients were assessed on clinical grounds and relevant investigations e.g. KOH

preparations, Tzanck smear and histopathology was carried out. These patients were enrolled in the study after taking informed consent. Confidentiality was assured. Patient's biodata, CD4 count and mucocutaneous lesions found were recorded on a predesigned proforma

Data were analyzed using SPSS version 20. Quantitative data e.g. age, duration was presented by calculating means and standard deviations, whereas qualitative data e.g. sex and different mucocutaneous lesions like viral infections, bacterial infections, fungal infections, oral candidiasis, parasitic infestations, seborrheic dermatitis, papulosquamous disorders, drug reactions, hair changes and nail changes were presented in the form of frequencies and percentages. Data were stratified for age, gender, CD4 count, duration of disease and stage of disease. Chi-square test was used post-stratification with P-value <0.05 considered as significant.

Results

A total of 170 patients were studied. Age ranged between 16 and 60 years with a mean of 41.9±8.2 years. 27 (15.9%) patients were between 16 to 30 years of age and 143 (84.1%) patients were between 31 to 60 years of age. There were 113 (66.5%) male patients and 57 (33.5%) female patients.

Table 1 Distribution of manifestations (n=170).

	N (%)
Viral infections	90 (53)
Bacterial infections	82 (48.2)
Fungal infections	63 (37)
Oral candidiasis	28 (16.5)
Parasitic infestation	49 (28.8)
Seborrheic dermatitis	51 (30)
Papulosquamous disorders	14 (8.2)
Drug reactions	17 (10)
Hair changes	17 (10)
Nail changes	51 (30)
Miscellaneous	17 (10)

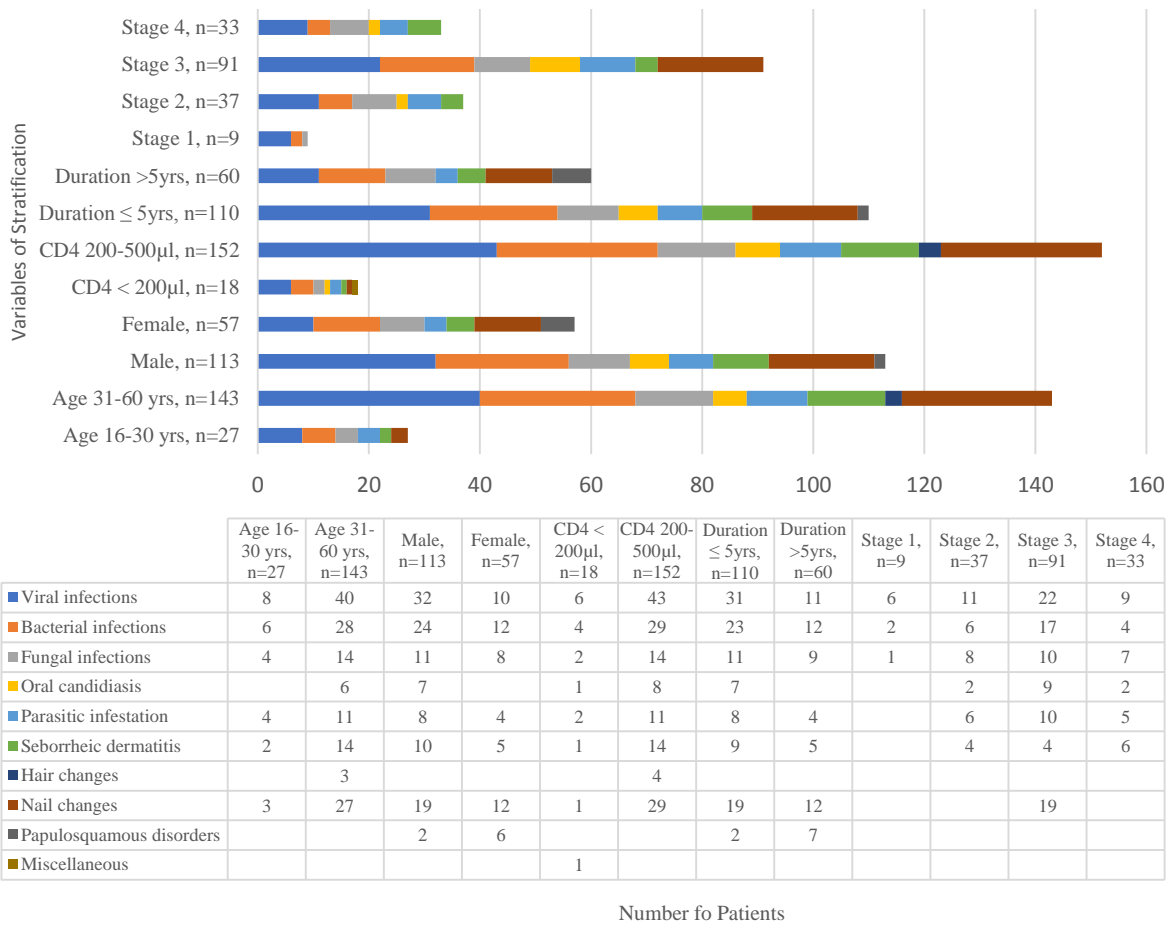


Figure 2 Stratification of Mucocutaneous manifestations

Table 2 P-values of Mucocutaneous manifestations on Stratification

	Age (years)	Gender	CD4 Count/µL	Duration (years)	Stage of disease
Viral infections	0.860	0.124	0.655	0.154	0.061
Bacterial infections	0.752	0.977	0.749	0.888	0.819
Fungal infections	0.436	0.400	0.402	0.333	0.326
Oral candidiasis	0.278	0.054	0.958	0.045	0.620
Parasitic infestation	0.231	0.988	0.558	0.882	0.537
Seborrheic dermatitis	0.697	0.986	0.605	0.972	0.064
Hair changes	0.447	NA	0.486	NA	NA
Nail changes	0.331	0.499	0.154	0.659	0.000
Papulosquamous disorders	NA	0.010	NA	0.006	NA
Miscellaneous	NA	NA	0.003	NA	NA

Majority of the patients, 91 (53.5%) had stage 3 disease and minimum number of patients i.e. 9 (5.3%) belonged to stage 1 disease. 37 (21.8%) patients had stage 2 disease and 33 (19.4%) patients had stage 4 disease (WHO clinical staging of HIV/ AIDS was used). CD4 count

<200/µl was observed in 18 (10.6%) patients while CD4 count 200-500/µl was seen in 152 (67.7%) patients. Mucocutaneous manifestations found in 143 (84.1%) patients while 27 (15.9%) patients did not show any mucocutaneous manifestations.

Frequency of mucocutaneous lesions were as follows: viral infections in 90 (53.0%) patients, herpes zoster 20%, herpes simplex 3%, warts 20%, molluscum contagiosum 5%, others 5%; bacterial infections in 82 (48.2%), furunculosis 7%, folliculitis 24%, ecthyma 1.2%, others 16%); fungal infections in 63 (37.0%) patients, tinea pedis 18%, tinea corporis 15%, tinea capitis 2%, others 2%); hair changes in 51 (30.0%) patients; seborrheic dermatitis in 51 (30.0%) patients; parasitic infestation in 49 (28.8%) patients; oral candidiasis in 28 (16.5%) patients; drug reactions and hair changes in 17 (10.0%) patients; papulosquamous disorders in 14 (8.2%) patients (**Table 1**).

Stratification with regard to age, gender, CD4 count, stage of disease and duration of disease was carried out and presented in **Figure 1** and **Table 2**. No statistically significant difference was found in majority of strata ($p>0.05$).

Discussion

Dermatological manifestations are common in patients of HIV. They may occur anytime during the course of disease. In the primary stage of infection, a generalized morbilliform eruption may occur while later on the disease is characterized by several infectious, inflammatory and neoplastic dermatoses.¹²

Skin diseases act as indicators of HIV and AIDS. The clinical diagnoses of skin diseases have been found to correlate with histopathological findings even in HIV patients.¹³ Hence, good clinical acumen is essential to make correct diagnoses of skin problems in these patients.

The epidemiological data of present study showed that males were predominantly affected. This was comparable to the study done by Supanaranond *et al.*¹⁴ that also showed that

males are primarily affected by this life-threatening disease. The commonest age group in our study was 31-60 years; this was same as a previous study conducted by Singh *et al.*¹⁵ in India.

In present study out of 170 patients, 143 (84.1%) were having multiple 479 mucocutaneous manifestations. This was similar to the findings of Jeffery *et al.*¹⁶ 16 86% and Pitche *et al.*¹⁷ 82.5%. However, the prevalence in this study was lower than that of the studies conducted by Edith *et al.*¹⁸ (93.5%), Sivayathorn *et al.*¹⁹ (90%), Uthayakyma *et al.*²⁰ (91.4%) and Coldiron *et al.*²¹ (92%).

In this study infectious and noninfectious manifestations were noted. The most common mucocutaneous lesions were observed viral infections in 90 (53.0%) patients, bacterial infections in 82 (48.2%) patients, fungal infections in 63 (37.0%) patients, hair changes in 51 (30.0%) patients, seborrheic dermatitis in 51 (30.0%) patients, parasitic infestation in 49 (28.8%) patients, oral candidiasis in 28 (16.5%) patients, drug reactions and hair changes in 17 (10.0%) patients, papulosquamous disorders 14 (8.2%) patients.

Herpes zoster involving multiple dermatomes was seen in 11.3% of the patients in our study. Multidermatomal herpes zoster has been seen in a previous study by Shobana *et al.*²² with a frequency of 6%.

In present study, seborrheic dermatitis was present in 30% while several studies have reported seborrheic dermatitis in patients ranging from 15.62%²³ to 83%.²⁴

The cause of seborrheic dermatitis is unknown, but investigators believe that alteration in the immune system in HIV-AIDS, changes the

response of the skin to the yeast, *Pityrosporum ovale*, leading to a higher rate of infection.²⁵

Oral candidiasis was seen in 16.5% in current study. Two earlier studies Shashikumar *et al.*²⁶ and Halder *et al.*¹³ reported candidiasis 14% and 17.5%, respectively, which is consistent with our study results.

Nichols *et al.*²⁷ stated that bacterial infections in HIV were often underrepresented. In our study we found 48.2% cases of bacterial infection. Rosenthal *et al.*²⁸ found its association in patients with CD4 counts between 200 and 500/ μ l. In present study, majority of the patients were having CD4 count 200-500/ μ l. It could be an important clinical marker of HIV infection, particularly in patients at increased risk of developing opportunistic infection.

Conclusion

A high prevalence of dermatological lesions in HIV-infected patients was seen in the present study. Most common mucocutaneous manifestation was viral infections followed by bacterial and fungal infections.

Mucocutaneous manifestations are useful clinical predictors of the HIV infection. These may present with unusual and atypical manifestations in the course of the HIV infection. So, a high level of suspicion for the HIV infection has to be kept in mind by the physicians during the investigations. An early detection of HIV optimizes the chemoprophylaxis for many opportunistic mucocutaneous infections.

References

1. Erdal E. Cutaneous Manifestations of HIV Disease. [Online]. [cited: 2009 Aug 12] Available from: <http://www.emed.med.com/article/1133746-overview>

2. USAIDS HIV/AIDS Health Profile for Pakistan-November 2010 [Online] [cited: 2011 Feb 8] Available from: http://www.usaid.gov/our_work/global_health/aids/Countries/asia/pakistan.htm
3. Skin and Mucocutaneous manifestations of HIV infection/AIDS, Chapter 8, In: Specialist's Training and Reference module. National AIDS Control Organisation: New Delhi: 2002. p. 71-81.
4. Verma KK. HIV infection and dermatological and venereal diseases. Abstract book - International conference on opportunistic pathogens in AIDS (ICOPA-INDIA) 2006. p. 31.
5. Wadhwa A, Kaur R, Aggarwal SK, Jain S, Bhalla P. AIDS related opportunistic mycoses seen in the tertiary care Hospital in North India. *J Med Microbiol.* 2007;**56**:1101-6.
6. Nnoruka EN, Chukwuka JC, Anisuiaba B. Correlation of mucocutaneous manifestations of HIV/AIDS infection with CD4 counts and disease Progression. *Int J Dermatol.* 2007;**46** Suppl 2:14-8.
7. Bunker CB, Staughton RCD. HIV-associated disease: dermatology. In: Gazzard BG, ed. *AIDS Care Handbook*. London: Mediscript; 2002. P. 115-39.
8. Hawkins T. Appearance-related side effects of HIV-1 treatment. *AIDS Patient Care STDS.* 2006;**20**:6-18.
9. Attili VS, Singh VP, Sundar S, Gulati AK, Varma DV, Rai M *et al.* Relationship between skin diseases and CD4 cell counts in a hospital base cohort of HIV infected adults in North India. *J Indian Acad Dermatol.* 2008;**9**:20-5.
10. Aydin OA, Karaosmanoglu HK, Korkusuz R, Ozeren M, Nazlican O. Mucocutaneous manifestations and the relationship to CD4 lymphocyte counts among Turkish HIV/AIDS patients in Istanbul, Turkey. *Turk J Med Sci.* 2015;**45**:89-92.
11. Goodman DS, Teplitz ED, Wishner A, Klein RS, Burk PG, Hershenbaum E. Prevalence of cutaneous disease in patients with An AIDS-related complex. *J Am Acad Dermatol.* 1987;**17**:210-20.
12. Azfar NA, Khan AR, Zia MA, Humayun A, Malik LM, Jahangir M. Frequency of mucocutaneous manifestations in HIV positive Pakistani patients. *J Pak Assoc Dermatol.* 2011;**21**:149-53.
13. Halder S, Banerjee S, Halder A, Pal PR. Skin diseases in HIV-infected patients:

- impact of immune status and histological correlation. *Indian J Sex Trans Dis.* 2012;**33**:65-7.
14. Supanaranond W, Desakorn V, Sitakalin C, Naing N, Chirachankul P. Cutaneous manifestations in HIV positive patients. *Southeast Asian J Trop Med Public Health.* 2001;**32**:171-6.
 15. Singh H, Singh P, Tiwari P, Dey V, Dulhani N, Singh A. Dermatological manifestations in HIV-infected patients at a tertiary care hospital in a tribal (Bastar) region of Chhattisgarh, India. *Indian J Dermatol.* 2009;**54**:338-41.
 16. Jeffery HS, Muz P, Cabral P, Jhomb K. Dermatological manifestations in HIV infected patients. *Mayo Clinic Proc.* 1999;**74**:658-60.
 17. Pitche P, Techangai-Walla K, Napo-Koura G. Prevalence of skin manifestations in AIDS patients in the Lome-Tkom University Hospital (Togo). *Sante.* 1995;**5**:349-52.
 18. Edith NN, Judith CC, Chukwuka A. Correlation of mucocutaneous manifestations of HIV/AIDS infection with CD4 cell counts and disease progression. *Int J Dermatol.* 2007;**46**:14-8.
 19. Sivayathorn A, Sirhra B, Leesanguankal W. Prevalence of skin diseases in patients infected with HIV in Bangkok, Thailand. *Ann Acad Med Singapore.* 1995;**24**:528-33.
 20. Uthayakumar S, Nandwani R, Drinkwater T, Nayagam AT, Darley CR. The prevalence of skin diseases in HIV infection and its relationship to the degree of immunosuppression. *Br J Dermatol.* 1997;**137**:595-8.
 21. Coldiron BN, Berstreser PR. Prevalence and clinical spectrum of skin disease in patients with HIV. *Arch Dermatol.* 1989;**125**:357-61.
 22. Shobana A, Guha SK, Neogi DK. Mucocutaneous manifestations of HIV infection. *Indian J Dermatol Venereol Leprol.* 2004;**70**:82-6.
 23. Pai G. Cutaneous manifestations of HIV infection. *Indian J Dermatol Venereol Leprol.* 1997;**63**:35-7.
 24. Mathes LE, Hayes KA, Kociba G. Evidence that high-dose zidovudine at the time of retrovirus exposure reduces antiviral efficacy. *Antimicrob Agents Chemother.* 1996;**40**:2183-6.
 25. Brannon H. Seborrheic dermatitis and AIDS. [Online] 2006 [cited: 2015 February 16]; Available from: <http://www.dermatology.about.com/bio/8905.htm>.
 26. Shashikumar BM, Harish MR, Hanumanthayya K, Bhagwat PV, Tophakhane R. CD4 Count: A Monitoring Tool in HIV. *Webmed Central Dermatol.* 2012;**3**:WMC003274.
 27. Nichols L, Balogh K, Silverman M. Bacterial infections in the acquired immune deficiency syndrome. Clinicopathologic correlations in a series of autopsy cases. *Am J Clin Pathol.* 1989;**92**:787-90.
 28. Rosenthal D, LeBoit PE, Klumpp L, Berger TG. Human immunodeficiency virus-associated eosinophilic folliculitis. A unique dermatosis associated with advanced human immunodeficiency virus infection. *Arch Dermatol.* 1991;**127**:206-9.