

Case Report

Bullous pemphigoid complicating human orf disease

Zerrin Ogretmen, Ceren Gül, Alper Ekinci, Taner Akalın*

Department of Dermatology, Çanakkale Onsekiz Mart University Faculty of Medicine, Turkey

* Department of Pathology, Ege University Faculty of Medicine, Turkey

Abstract Orf is a zoonosis caused by *Parapoxvirus* and transmitted to human by sheep. Bullous pemphigoid has been reported as an occasional complication following orf. We report a 51-year-old female who developed bullous pemphigoid 3 weeks following orf. The case is reported for its rare co-occurrence.

Key words

Orf, bullous pemphigoid, orf-induced immunobullous disease.

Introduction

Orf (Ecthyma contagiosum) is a zoonotic infection caused by *Parapoxvirus*, which is transmitted to human via sheep. Most common complications of orf are secondary infection, lymphangitis, lymphadenopathy and erythema multiforme.¹ There are a few rare case reports about subepidermal immunobullous disease affecting skin and/or mucous membranes following orf in the literature.⁴⁻⁷ We also present a case from our clinic about bullous pemphigoid following orf since it is a rare clinical situation.

Case Report

A 51-year-old female presented to our clinic with complaint of ulcerated lesions affecting feet, scalp, oral mucosa. Her complaint had started 4 days ago. Her medical history revealed that she also had been diagnosed as orf 3 weeks ago and had been treated with topical and systemic antibiotics. No other significant detail

had been obtained from her medical history and her family's medical history.

Dermatological examination revealed an erythematous and centrally crusted lesion of orf was present on the proximal of her left index finger (**Figure 1**). There were intact bullae on her scalp, trunk and limbs (**Figure 2**). An eroded plaque surrounded by remnants of bullae was detected on hard palate in oral mucosa. Rest of the systemic examination of the patient was completely normal.

In her laboratory tests, complete blood count, liver and renal function tests were normal. CRP was 3.05 mg/dl (N: 0-0.8mg/dl), erythrocyte sedimentation rate was 66 mm/s (N: 0-20 mm/s). A skin punch biopsy was performed with the differential diagnoses of bullous pemphigoid, erythema multiforme and bullous drug eruption. The result of histopathological examination and immunofluorescence examination was the diagnosis of bullous pemphigoid (**Figures 3 and 4**).

Address for correspondence

Dr. Zerrin Ogretmen

Department of Dermatology,

Çanakkale Onsekiz Mart University Faculty of

Medicine, Turkey

Email: zogretmen@gmail.com

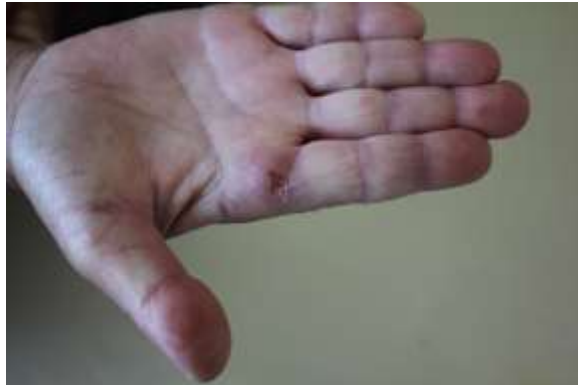

Figure 1 Centrally crusted lesion of orf present on the proximal to the root of right index finger.

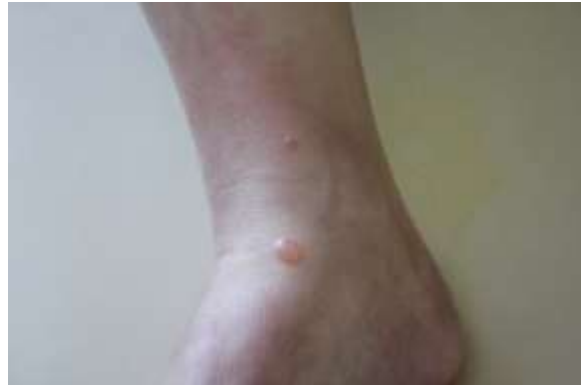

Figure 2 A large and small blister on diffuse erythema underneath present near right ankle.

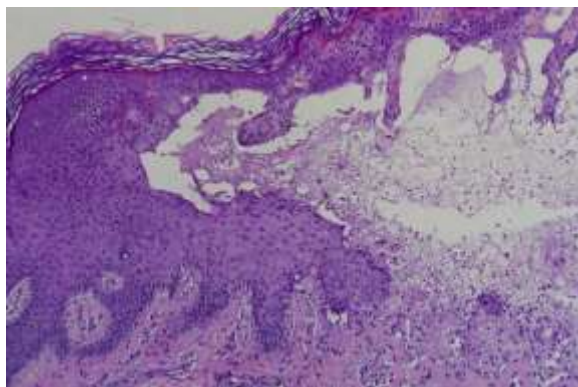


Figure 3 Histopathology of blister revealed subepidermal cleft with predominantly eosinophilic infiltrate.

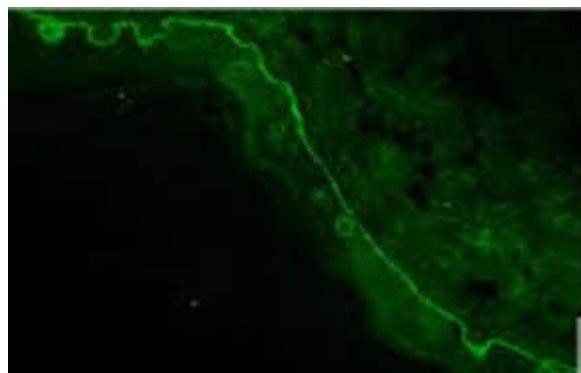


Figure 4 Immunofluorescence of perilesional skin showed lineal band of IgG and C3 at the dermoepidermal junction.

Discussion

In a case series with 5 patients of bullous pemphigoid following orf infection in the literature, bullous lesions have been reported to occur 3 weeks after the occurrence of orf infection.⁶ Also, in another case report, bullous lesions were reported to occur 3-4 weeks after the occurrence of orf infection.⁴ In a case report of pemphigoid of mucous membrane, it was reported that clinical findings appeared 4 weeks following orf infection.⁷ In our country Avci *et al.*⁸ have reported about the relationship of orf infection and bullous pemphigoid. In our case, the bullous lesions appeared approximately 3 weeks after the occurrence of orf lesion. No other related medical condition explaining this co-occurrence was detected in our patient. The clinical, histopathological and

immunofluorescence findings confirmed the diagnosis. Our patient was treated by topical corticosteroid cream. The relationship between orf and bullous pemphigoid has not been elucidated completely yet. More case reports regarding this clinical condition are needed.

Conclusion

Bullous pemphigoid following orf infection is a rare complication. There are a few case reports about bullous pemphigoid after orf infection in the literature. In our country, Avci *et al.*⁸ have been published the first case report about this togetherness. Our case is the second case diagnosed by macroscopic, histopathological and immunofluorescence findings.

References

1. Ozturk P, Sayar H, Karakas T, Akman Y. Erythema multiforme as a result of orf disease. *Acta Dermatovenerologica Alp Pannonica Adriat*. 2012;**21**:45-6.
2. Shahmoradi Z, Abtahi-Naeini B, Pourazizi, M, Meidani M. Orf disease following “Eid ul-Adha”: A rare cause of erythema multiforme. *Int J Prev Med*. 2014;**5**:912-4.
3. Agger WA, Webster SB. Human orf infection complicated by erythema multiforme. *Cutis*. 2014;**31**:334-8.
4. Alian S, Ahangarkani F, Arabsheybani S. A case of orf disease complicated with erythema multiforme and bullous pemphigoid-like eruptions. *Case Rep Infect Dis*. 2015;**2015**:105484.
5. White KP, Zedek DC, White WL, Simpson EL, Hester E, Morrison L *et al*. Orf-induced immunobullous disease: A distinct autoimmune blistering disorder. *J Am Acad Dermatol*. 2008;**58**:49-55.
6. Murphy JK, Ralfs IG. Bullous pemphigoid complicating human orf. *Br J Dermatol*. 2008;**134**:929-30.
7. Van Lingen RG, Frank RGJ, Koopman RJJ, Jonkman MF. Human orf complicated by mucous membrane pemphigoid. *Clin Exp Dermatol*. 2006;**31**:711-2.
8. Avci A, Avci D, Turasan A, Çınar SL. Orfun İndüklediği Bullöz Pemfigoid Olgusu. *Turk J Dermatol*. 2013;**7**:91-2.